



PRESENTING CLINICAL SIGNS

DATE History: New murmur. Drooling/panting suspected to be secondary to back pain. Has responded well to anti-inflammatories.

7/22/22

ECHOCARDIOGRAPHIC FINDINGS

2D, M-mode, and Doppler study.

PERFORMED BY:

Dr. Meredith Swart

INTERPRETED BY

Keith Blass, DVM,
MS, DACVIM
(Cardiology)

There is mild left atrial dilation. The mitral valve leaflets are mildly thickened and exhibit systolic prolapse. There is Doppler evidence of mitral regurgitation present. There is mild left ventricular dilation. Left ventricular systolic function is hyperdynamic. The aorta and aortic valve are normal. Right atrial and right ventricular dimensions are normal. The tricuspid valve is normal. The pulmonary artery and pulmonic valve are normal. No shunting lesions are visualized. No pericardial effusion or cardiac masses are seen.

PATIENT

Coco Tidwell

LA - 29.1 mm
LVIDd - 29.0 mm
LVIDs - 15.2 mm
FS - 47.6%
LVOT - 1.82 m/s
RVOT - 1.23 m/s

ASSESSMENT/RECOMMENDATIONS

SPECIES

Canine

Degenerative mitral valve disease

This examination demonstrates regurgitation of blood across Coco's mitral valve resulting from degenerative valve disease. Secondary to her regurgitation, Coco has mild dilation of both her left atrium and left ventricle, though her left ventricular systolic function is well-preserved. As only mild left heart chamber dilation is present, Coco's mitral valve disease appears to be well-compensated, and it's unlikely that her drooling or panting is cardiogenic in origin.

BREED

Shih Tzu

I recommend starting Coco on pimobendan (2.5 mg BID), as this medication should help to slow the progression of her mitral valve disease.

SEX

FS

Thoracic radiographs are recommended if Coco's panting persists, or if she develops labored breathing.

AGE

8 y

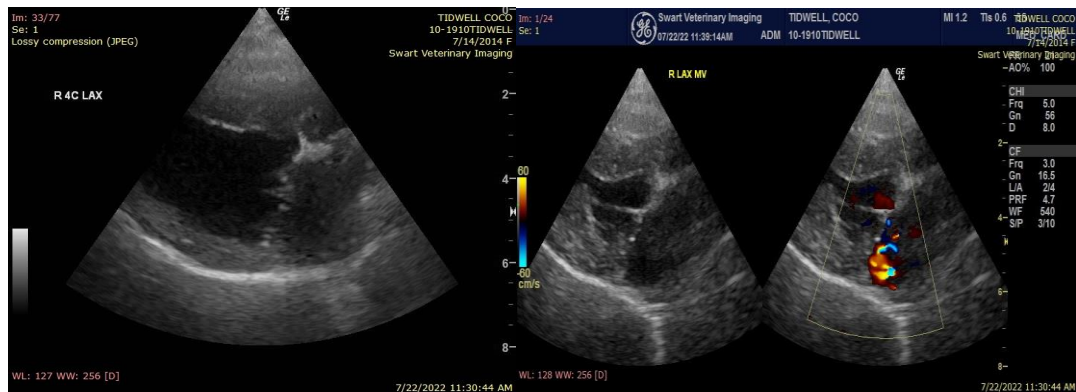
A recheck echocardiogram is recommended in 9 months.

WEIGHT

17 lb

HOSPITAL NAME

Swart Veterinary
Imaging



REFERRING VET

Dr.Swart

The information and recommendations provided are based on the images presented by the



DATE referring veterinarian. No evaluation can be communicated regarding pathology that was not visible in the image/video clips provided.

7/22/22 Thank you for this referral. If the clinical or image interpretation does not parallel your findings or if I can be of any further assistance please contact me.

PERFORMED BY: Keith Blass, DVM, MS, DACVIM (Cardiology)
Dr. Meredith Swart KeithBlass@gmail.com
631-804-5754

INTERPRETED BY

Keith Blass, DVM,
MS, DACVIM
(Cardiology)

PATIENT

Coco Tidwell

SPECIES

Canine

BREED

Shih Tzu

SEX

FS

AGE

8 y

WEIGHT

17 lb

HOSPITAL NAME

Swart Veterinary
Imaging

REFERRING VET

Dr.Swart